

Case Series

© 2022 Acosta-Farina et al.

Submitted: 09-12-2021

Accepted: 30-01-2022

License: This work is licensed under a [Creative Commons Attribution 4.0 International License](https://creativecommons.org/licenses/by/4.0/).

DOI: <https://doi.org/10.47338/jns.v11.1046>

Initial management of omphalocele using negative pressure wound therapy (NPWT) in Ecuador: A case series

Daniel Acosta-Farina,^{1*} Johan Aguayo-Vistin,² Cristian Cedeño-Moreira,² Vicente Salinas-Salinas,¹ Verónica Polit-Guerrero,² Daniel Acosta-Bowen,³ Jorge Oliveros-Rivero,²

1 Pediatric Surgery Department, Dr. Roberto Gilbert Elizalde Children's Hospital, Guayaquil-Ecuador

2 Pediatric Surgery Resident, Universidad Católica Santiago de Guayaquil, Guayaquil-Ecuador

3 Medical Doctor, Universidad Católica Santiago de Guayaquil, Guayaquil-Ecuador

Correspondence*: Daniel Acosta-Farina, M.D., Pediatric Surgery Department, Dr. Roberto Gilbert Elizalde Children's Hospital, Guayaquil, Ecuador, 090505. **E-mail**: acofa111@yahoo.es

KEYWORDS

Abdominal wall defect,
Negative pressure wound
therapy (NPWT),
Omphalocele

ABSTRACT

Background: Omphalocele is an abdominal wall defect. Herniated organs can be small or large intestine, liver, and stomach. The use of conventional techniques has always been a challenge for the surgeon. The goal of using NPWT is to provide a quick, simple, and effective method to reduce the eviscerated content and enlarge the visceral continent.

Case Presentation: The record of 3 patients with omphalocele was reviewed. There were two females and one male neonate. All the babies were born by C-section and were antenatally diagnosed for omphalocele. In all cases, NPWT was applied. Two cases were discharged in good condition while one patient with complex cardiac defects succumbed.

Conclusion: NPWT is an effective and safe alternative for omphalocele management.

INTRODUCTION

Omphalocele is an abdominal wall defect, the management of which has been quite challenging to the surgeons. [1] The use of mesh, silo, or hydrocolloid patches is not always successful. They are associated with a high rate of complications, need for frequent manipulation, and prolonged hospital stay, which can lead to nosocomial infections and wasting of resources. [3]

In the 1940s NPWT was first used to treat complex and difficult to heal wounds, nonetheless, its use in the pediatric population is fairly recent. [2] The goal of NPWT is to provide a quick, simple, and effective method to reduce the eviscerated content and enlarge the visceral continent. It dehydrates and accelerates the scarification of the amnions, allowing a definitive closure in lesser time. The closure must occur at an appropriate moment as premature closure may result in abdominal compartment syndrome. [4] The main aim is to present our experience with NPWT in neonates with omphalocele.

METHODS

Data of 3 patients with omphalocele, who were managed with NPWT at Roberto Gilbert Elizalde Children's Hospital in Guayaquil, Ecuador during the period from June to October 2021, were reviewed retrospectively.

The Technique of NPWT: All patients were treated with NPWT Welsuc® Guangzhou Rainhome Pharm Y Tech Co. Ltd China. This system is composed of: 1) Negative pressure device with pressure ranging from 50-225 mmHg; 2) 450 ml Recipient; 3) Adhesive sheets; 4) Suction cup and tubes; and 5) Absorbent sponges with various diameters: 10x7x3cm, 15x10x3cm, 20x10x3cm. In order to achieve good adherence and avoid contaminants, the omphalocele sac and abdominal wall were cleaned with 70% alcohol before the device placement. Once the surface was prepared, the defect and redundant skin margins were measured. The sponge should cover the defect entirely and extend 2 cm beyond the skin margins, allowing adequate pressure in all edges. Adhesive sheets were then placed, sealing the sponge. The central part of the sheet is perforated and the suction cup fixated, reinforcing it with extra sheets to avoid leaks. Tubes are placed and the recipient is connected to the negative pressure machine. Machine settings vary as needed.

The negative pressure used in all cases ranged from 50-175 mmHg. Tolerance was good, taking into account the patient's comorbidities and clinical status. The device was replaced every 10 days and the wound was uncovered to note the progress, scarification of the sac, and decide if adjustments

were needed. The omphalocele axis was constantly monitored to avoid vascular compromise.

CASE SERIES

Case 1: A female newborn weighing 2622g was born by C-section at 38 weeks of gestation to a 24-year-old primigravida with a prenatal diagnosis of omphalocele. The APGAR scores were 7-8-8. On examination, a giant omphalocele was seen with liver, stomach, and intestine as the contents of the sac (Fig. 1a). NPWT was placed using a continuous pressure of 100 mmHg (Fig. 1b,c). The patient developed severe pulmonary hypertension, which warranted high-frequency mechanical ventilation, pseudo-relaxation, and administration of a selective pulmonary vasodilator. Improvement was seen on her 7th day of life. Pressures on the NPWT were as high as 175 mmHg with good tolerance. On the 8th day, the NPWT system replacement was performed. Reduction of the defect size was observed (Fig. 1d). The device was set on 100 mmHg of pressure, which progressed to 125. Enteral stimulation was started. On the 20th day of life NPWT was removed, amnios contraction was observed (Fig. 1e). Two (2)% Hydroalcoholic Chlorhexidine was used as part of treatment to aid in scarification. On the 29th day, the patient showed good enteral tolerance and adequate bowel movements so she was discharged.

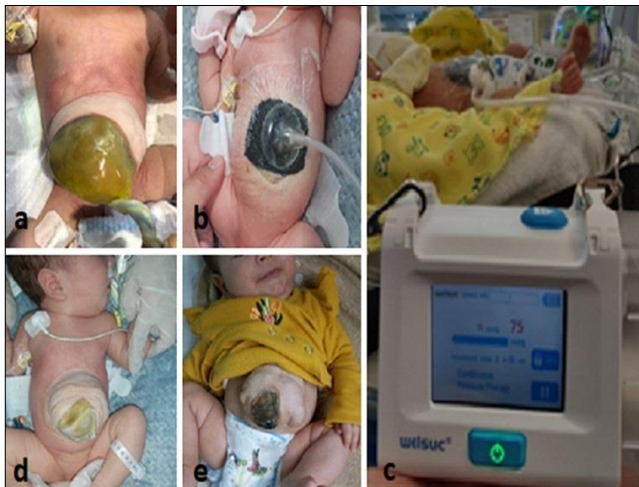

Figure 1: a) Giant omphalocele with herniation of liver, intestine and stomach. b) NPWT placement. c) welsuc® system, used in all patients. d) Defect size reduction due to amnios contraction, seen at day 20. e) Amnios scarification 9 days after NPWT removal.

Case 2: A male newborn weighing 3426 g was born by C-section at 40 weeks of gestation to a 16-year-old primigravida with a prenatal diagnosis of omphalocele. APGAR scores were 6-8-8. On examination, omphalocele was seen with liver as its content. The defect size was >5 cm (Fig. 2a). NPWT was placed using a continuous pressure of 100 mmHg. Echocardiography showed complex cardiopathy with truncus arteriosus, aortic arch stenosis, ductus arteriosus, single coronary artery, severe hypertension, and moderate

left vascular pulmonary hyper-resistance. Mechanical ventilation was required for 7 days, during that period bowel movements were present. On the 9th day, NPWT was removed, a total reduction of the omphalocele was observed (Fig. 2c). The closure was performed a week after due to cardiac instability (Fig. 2d). The patient was discharged at 1 month of age.

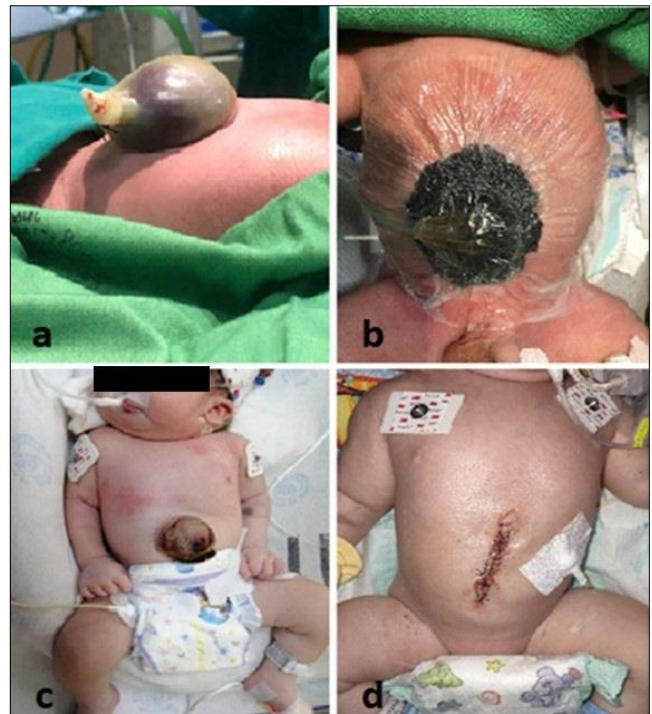

Figure 2: a) Omphalocele with liver herniation. b) NPWT system placement on 1st day of life. c) NPWT removal on the 9th day of life. d) Closure of the abdominal wall on the 16th day of life.

Case 3: A female newborn weighing 2470 g was born by C-section at 40 weeks of gestation to a 32-year-old mother (4th pregnancy) with a prenatal diagnosis of omphalocele. APGAR scores were 7-9-9. On examination, omphalocele was seen with liver and intestinal herniation. The defect size was >8 cm (Fig. 3a). NPWT was placed using a continuous pressure of 100 mmHg (Fig. 3b).

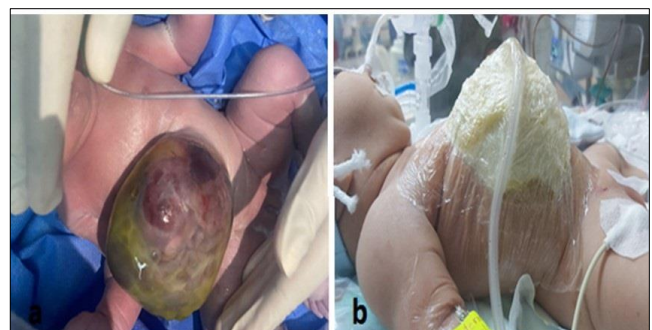


Figure 3: a) Giant omphalocele with herniation of liver and intestine. b) NPWT system applied

Respiratory Insufficiency was present since birth and required mechanical ventilation and vasoactive drugs. In complementary studies, there were several findings: small perimembranous VSD, ASD, 4.5 mm

Ostium secundum, and PDA. On the 3rd day of life, she developed bradycardia necessitating cardiac massage and epinephrine administration. Her hemodynamic instability never improved and succumbed to it.

DISCUSSION

Omphalocele management has always been a challenge for the surgeon. Currently, there are no extensive case-control studies that strongly recommend NPWT as part of the treatment, only case reports or case series which show satisfactory clinical experience. [5]

The NPWT system applies regulated negative pressure upon the surface of a wound or as in this case, on the abdominal wall. Its effects are attributed to the mechanical stimulus generated by the sub-atmospheric pressure, which diminishes extracellular fluid. It also allows microcirculation, perfusion of oxygen and nutrients which aids in granulation tissue proliferation. It reduces bacterial load and improves scarring; therefore, it can be used on infected wounds.

NPWT is applied in omphalocele regardless of the defect size. It applies a mechanical pressure upon the viscera that progressively and atraumatically reduces it while creating space for it in the abdominal cavity. This was seen in our patients. [6]

There were no limitations regarding the use of NPWT in our cases. If available, management is simple. There are no negative hemodynamic repercussions seen even if the patient is premature or undergoes mechanical ventilation. As mentioned by Sorolla et al in their report, significant improvement can be seen with 9 days of therapy. In our cases, improvement was also seen around the 9th-10th day of NPWT use.

The main objective of definitive aponeurotic closure of this big defect is to allow the patient to achieve adequate progressive development. Respiratory and intestinal compromise should be taken into account, especially abdominal compartment syndrome. [7] Not only were these goals met in our patients, but we were also able to start early enteral nutrition with good tolerance. Our study is a presentation of initial results, it is too early to conclude that NPWT is not

recommended in patients with omphalocele associated with complex cardiac anomalies, as was seen in our second patient who had complex cardiac anomalies, but successfully managed with NPWT.

NPWT has a direct effect on the size of the defect. It reduces hospital stay and costs. Survival of these patients is determined mainly by the presence of comorbidities as mentioned by Adesola et al. [8] In our third case, results related to omphalocele therapy were satisfactory but the patient died due to cardiac complications.

NPWT system can be used on patients with omphalocele who have damaged sac, where viscera are exposed. Using this system, viscera are contained and pressure is equally applied aiding in the reduction. As in other congenital defects (gastroschisis), partial or total grafts can be used to achieve better closure. [9] None of our patients needed grafts for closure.

Despite being a retrospective study of a small number of patients, it was observed that patients experienced less pain even when awake, due to the absence of tissue traction. Other important reasons were: skin edges were covered and protected and amnios was preserved and will eventually form part of neo-epithelialization due to the NPWT action. We suggest conducting studies with a large number of patients and including patients with other abdominal wall defects such as gastroschisis.

In conclusion, NPWT is an effective and safe alternative for omphalocele management. It can be used on very low-weight neonates, without the risk of amnios rupture even if they are under mechanical ventilation.

Acknowledgements: Nil

Conflict of Interest: None.

Source of Support: Nil

Consent to Publication: Author(s) declared taking informed written consent for the publication of clinical photographs/material (if any used), from the legal guardian of the patient with an understanding that every effort will be made to conceal the identity of the patient, however it cannot be guaranteed.

Author Contributions: Author(s) declared to fulfil authorship criteria as devised by ICMJE and approved the final version.

REFERENCES

1. Aldridge B, Ladd AP, Kepple J, Wingle T, Ring C, Kokoska ER. Negative pressure wound therapy for initial management of giant omphalocele. *Am J Surg*. 2016; 211:605-9.
2. Kilbride KE, Cooney DR, Custer MD. Vacuum-assisted closure: a new method for treating patients with giant omphalocele. *J Pediatr Surg*. 2006; 41:212-5.
3. Binet A, Gelas T, Jochault-Ritz S, Noizet O, Bory JP, Lefebvre F, et al. VAC® therapy a therapeutic alternative in giant omphalocele treatment: a multicenter study. *J Plast Reconstr Aesthet Surg*. 2013; 66:e373-5.
4. David VL, Neagu MC, Sosoi A, Stanculescu MC, Horhat FG, Stroescu RF, et al. Combined staged surgery and Negative-Pressure Wound Therapy for closure of a giant omphalocele. *Case Rep Pediatr*. 2021; 2021:5234862.
5. McBride CA, Stockton K, Storey K, Kimble RM. Negative pressure wound therapy facilitates closure of large

- congenital abdominal wall defects. *Pediatr Surg Int.* 2014; 30:1163-8.
6. Sorolla JP, Cabello R, Fontbona M, Dagnino B, Obaid D, Giugliano C. [Experience in management of wounds and abdominal wall defects with continuous negative pressure in newborns]. *Rev Chil Cir Plast.* 2010; 8:57-62. Article in Spanish.
 7. Wilcinski SL. Use of a vacuum-assisted device in a neonate with a giant omphalocele. *Adv Neonatal Care.* 2010; 10:119-26.
 8. Akinkuotu AC, Sheikh F, Olutoye OO, Lee TC, Fernandes CJ, Welty SE, et al. Giant omphaloceles: surgical management and perinatal outcomes. *J Surg Res.* 2015; 198:388-92.
 9. Lorca García C, Pérez García A, Hortelano Otero A, Centeno Silva JA, López Blanco E, Gutiérrez Ontalvilla P, et al. [Use of vacuum therapy at La Fe Children's Hospital in Valencia (Spain): experience and results]. *Cir Plást Iberolatinoam.* 2011; 37:S41-S52. Article in Spanish.
 10. Carrera Matute J, López Vidaurre M, Santos Luna H, Hernández F, Sánchez Jarquín M. [Use of Vacuum Therapy System in closure of Complicated Gastroschisis]. *Rev Cir Guatemalteco.* 2015; 21:60-2. Article in Spanish.
-